

Clinical Practice

Artefacts in oral incisional biopsies in general dental practice: a pathology audit

J Seoane¹, PI Varela-Centelles¹, JR Ramírez², J Cameselle-Teijeiro³, MA Romero¹

¹Stomatology Department, School of Medicine and Dentistry, University of Santiago de Compostela, Spain; ²Department of Pathology, "Gómez Ulla" University and Military Hospital, Madrid, Spain; ³Department of Pathology, University Hospital, Santiago de Compostela, Spain

OBJECTIVES: To investigate the artefacts in oral biopsies taken by general dental practitioners (GDP) and oral and maxillofacial surgeons (O&MF) and to assess the concordance of clinical and pathological diagnoses.

DESIGN: Cross-sectional investigation.

SETTING: Primary care and hospital practice.

MATERIAL AND METHODS: A total of 354 randomly selected oral biopsy samples studied by the same pathologist.

MAIN OUTCOME MEASURES: Clinical and pathological diagnoses – prevalence and location of surgical handling artefacts: crush, splits, haemorrhage and fragmentation.

RESULTS: Artefacts identified in GDPs biopsies: crush 27.1%; haemorrhage 19.8%; splits 11.3%; and fragmentation 6.2%. O&MFs biopsies showed: crush 10.2%; splits 13%; fragmentation 2.3%; and haemorrhage 8.5%. No differences in split or fragmentation were identified between GDPs and O&MFs. Crush ($\chi^2 = 16.76$; $P = 0.000$) and haemorrhage ($\chi^2 = 9.31$; $P = 0.003$) were more frequently identified in GDPs biopsies. Concordance between clinical and pathological diagnoses was excellent ($\kappa > 0.75$) for both groups in all disorders considered.

CONCLUSIONS: The elicited clinical knowledge, the quality of the samples sent to the pathologists seem to suggest the advisability for the GDPs to perform diagnostic biopsies.

Oral Diseases (2004) 10, 113–117

Keywords: biopsy; oral cancer; precancer; dentistry; artefact; oral surgery

Introduction

The application of biopsy in the management of oral lesions includes a sequence of steps: adequate data

collection, competent diagnostic skills, proper surgical management, evaluation and interpretation of the pathologist's report and comprehensive patient follow-up (Bermejo Fenoll, 1998).

Numerous types of artefacts can affect the biopsy specimen. Artefact refers to an artificial structure or tissue alteration on a prepared microscopic slide – the result of an extraneous factor (Bernstein, 1978). These have been shown to result from crush (by forceps), fragmentation, injection, improper fixation and freezing (Bernstein, 1978; Margarone, Natiella and Vaughan, 1985).

Selection of both technique and surgical instruments to avoid artefacts is controversial: the use of a CO₂ laser beam for the procurement of diagnostic biopsy specimens is compromised by thermal cytological artefacts (Eversole, 1997). Problems of this nature are also encountered with electrocautery (Margarone *et al*, 1985). Punch biopsy has been suggested to reduce artefacts (Moule, Parsons and Irvine, 1995), although it could not be confirmed under controlled experimental conditions (Seoane *et al*, 2002).

Artefacts related to an incorrect surgical handling of the specimens seem to be common in oral mucosal biopsy material, and oral biopsies obtained by oral and maxillofacial surgeons (O&MFs) (Moule *et al*, 1995). No information is available on the performance of general dental practitioners (GDPs). No comparisons between the two groups have been described in scientific literature so far.

The aims of this study were to investigate the artefacts produced in oral biopsy material by general dental practitioners and O&MFs and to identify the concordance of clinical and pathological diagnosis in both groups. The accomplishment of these objectives may contribute to define the *dos and dont's* when oral mucosal biopsies are performed by GDPs.

Methods and materials

Sample size was determined considering bilateral hypothesis (two tails) assuming an α risk of 0.05 and

$\beta = 0.20$. The minimum identifiable difference between groups was set at 15%, estimating a frequency of artefacts of 45% for the O&MS group (Moule *et al*, 1995). A minimum sample size of 173 specimens for each group was obtained.

A simple random sampling selection carried out at the pathology service of the 'Gómez-Ulla University and Military Hospital' in Madrid (reference hospital for GDP and O&MS oral biopsies) provided 177 oral biopsies performed by GDPs and 177 by O&MSs.

The incisional biopsies were carried out using a standard technique; a conventional elliptical biopsy was performed by scalpel. An elliptical v-shaped wedge was obtained and grasped carefully at one end with a toothed tissue forceps for careful removal by undercutting.

Specimens were immediately introduced into a wide-mouthed container and fixed in a copious amount of 10% formol-buffered saline for 24 h. All specimens were cut with a new disposable knife for every section and orientated before embedding in paraffin. Samples were cut in 4- μ m sections and stained with haematoxylin & eosin. All specimens were processed under the same protocol.

All 354 samples were studied by the same pathologist. Clinical and pathological diagnoses were considered for each specimen. Histological examination assessed both prevalence and location of surgical handling artefacts (squeeze artefacts): crush, splits, haemorrhage and fragmentation, according to previously described criteria (Moule *et al*, 1995; Seoane *et al*, 2002).

Statistical analysis was performed by means of a SPSS + 8.0 statistical package. Pearson's chi-square was used to compare proportions. The level of significance chosen was 5%. Concordance between clinical and pathological diagnoses was determined by grouping the disorders under four headings (inflammatory, benign tumoral disorders, oral precancer and oral cancer) and using the Cohen's kappa test with three ranges of values: excellent ($\kappa > 0.75$), moderate ($0.40 \leq \kappa \leq 0.75$) and poor ($\kappa < 0.40$) (Fleiss, 1986).

Results

Oral mucosa was the most frequently biopsied area both by GDPs (75.1%) and O&MSs (62.7%) (Table 1). The biopsies by the GDPs were diagnosed as inflammatory disorders and oral precancer in up to 67.2% of the pathologist's reports, whereas most biopsies (65%) performed by O&MSs were diagnosed as benign or malignant tumoral disorders.

Table 1 Biopsy sites within the oral cavity

Locations	GDP [<i>n</i> (%)]	O&MS [<i>n</i> (%)]
Oral mucosa	133 (75.1)	111 (62.7)
Lips	13 (7.3)	21 (11.9)
Palate	8 (4.5)	9 (5.1)
Tongue	5 (2.8)	17 (9.6)
Floor of the mouth	18 (10.2)	19 (10.7)

Table 2 Frequency and location of the artefacts found in biopsies performed by GDPs or O&MSs

	GDP [<i>n</i> = 177; <i>n</i> (%)]	O&MS [<i>n</i> = 177; <i>n</i> (%)]
Crush		
None	129 (72.9)	159 (89.8)
Base	38 (21.5)	16 (9)
Superficial	10 (5.6)	2 (1.1)
Splits		
None	157 (88.7)	154 (87)
Superficial	14 (7.9)	11 (6.2)
Deep	6 (3.4)	12 (6.8)
Fragmentation		
None	166 (93.8)	173 (97.7)
Superficial	4 (2.3)	2 (1.1)
Deep	7 (4)	2 (1.1)
Haemorrhage		
None	142 (80.2)	162 (91.5)
Edge	34 (19.2)	15 (8.5)
Specimen	1 (0.6)	0 (–)

When all 354 samples were considered, the most frequently identified artefact in GDPs' (27.1%) and O&MSs' (10.2%) biopsies was the crush. This artefact was more commonly found on inflammatory lesions: 27.3% vs 15.3% ($\chi^2 = 6.74$; $P = 0.014$).

The artefacts identified in GDPs' biopsies were by frequency: crush 27.1%; haemorrhage 19.8%; splits 11.3%; and fragmentation 6.2%. No statistically significant differences in the proportion of artefacts were observed when the location of the original lesion was considered ($P > 0.05$). O&MSs' biopsies showed crush in 10.2% of the specimens; splits 13%; fragmentation 2.3% and haemorrhage in 8.5% of the samples. The artefacts identified on histopathological examination are listed in detail in Table 2 and illustrated in Figures 1–3.

No statistically significant differences in terms of split and fragmentation were identified between GDPs' and O&MSs' specimens. However, crush ($\chi^2 = 16.76$; $P = 0.000$) and haemorrhage ($\chi^2 = 9.31$; $P = 0.003$) were more frequently identified in those biopsies taken by GDPs (Figure 4). Concordance between clinical and pathological diagnoses was excellent ($\kappa > 0.75$) for both groups (GDPs and O&MSs) in all disorders considered (Table 3). No autolysis or phenomena associated with inadequate tissue fixation were observed. Pathological diagnosis was not impaired in any of the cases by the improper surgical handling of the specimens.

Discussion

Who should perform oral biopsies? Several authors answer this question saying that any dental practitioner possesses sufficient skill to remove and submit the tissue to a pathologist (Yellowitz *et al*, 1998). However, the number of primary care dentists who offer oral biopsy either on a routine or selective bases is scarce in Europe [12% in Northern Ireland (Cowan, Gregg and Kee, 1995), 21% in UK (Warnakulasuriya and Johnson, 1999), and 24.5% in Spain (Seoane, Varela-Centelles and Diz Dios, 1999)], probably because of a lack of instruction (Jaber *et al*, 1997). A significant relationship

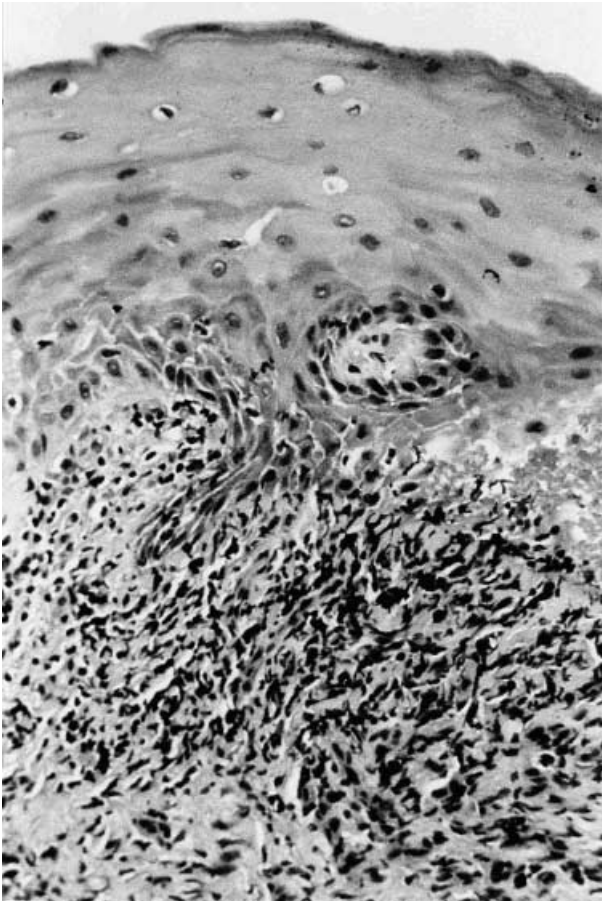


Figure 1 Oral mucosa specimen with crush of the inflammatory population (lymphocytes) of epithelium's underlying stroma (H&E; 400x)

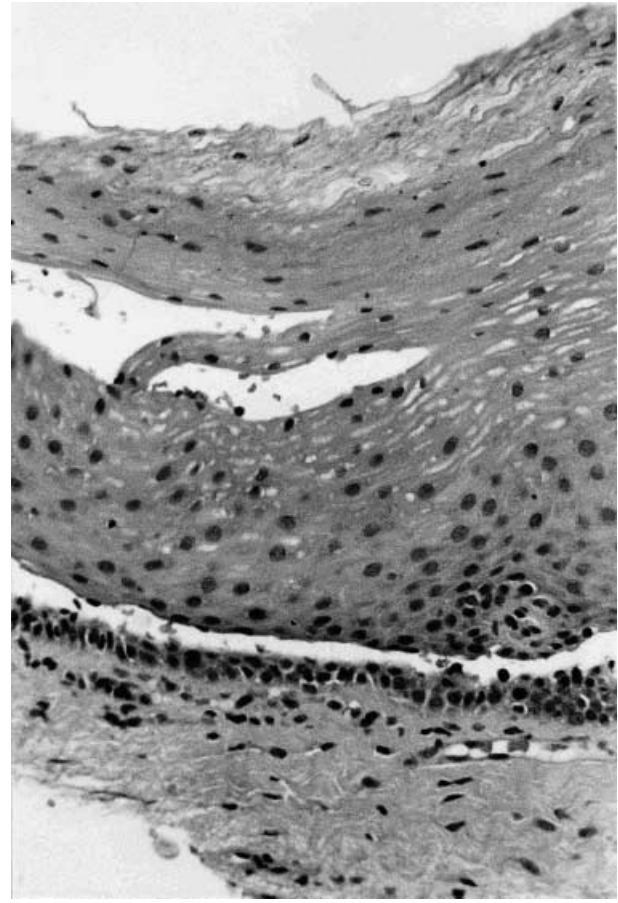


Figure 2 Artefactual suprabasal cleavage plane within the oral epithelium mimicking a penphigus (H&E; 400x)

emerged between the use of biopsy as a diagnostic tool and whether or not the dentist performed it while being an undergraduate student. Those who had performed it at dental school were more likely to have done so in their offices (Margarone, Natiella and Natiella, 1984). Several tissue alterations during oral biopsy procedures have been described. Preparation of the area of biopsy with iodine tincture or other coloured solutions should be avoided as it can interfere with tissue processing and staining procedures (Daley, Lovas and Wysocki, 1986). Intralesional injection of anaesthetic solution should also be avoided as it can produce haemorrhage with extravasation and separation of connective tissue bands with vacuolization (Margarone *et al*, 1985).

Artefacts incurred during handling of tissue are a major source of diagnostic problems. In some cases, this squeeze artefact is easily recognized but in other instances the specimen may be useless for an accurate diagnosis (Zegarelli, 1978). Squeeze artefacts are a form of tissue distortion resulting from even the most minimal compression of tissue that groups crush, haemorrhage, splits, fragmentation and pseudocysts, and are usually caused by forceps, by using a stitch for traction or by a dull scalpel blade (Bernstein, 1978; Zegarelli, 1978; Lynch and Morris, 1990; Seoane *et al*, 2002).

In agreement with previous reports (Moule *et al*, 1995; Seoane *et al*, 2002), our results suggest that crush, splits and haemorrhage are the artefacts most frequently found in incisional oral biopsies. Crush and haemorrhage are significantly more common in biopsies performed by GDPs. This could be explained by the fact that inflammatory tissue is more prone to suffer crush when biopsied (Bernstein, 1978) and these disorders are predominant amongst GDPs' specimens.

The ability of the oral pathologist to interpret a biopsy correctly is directly proportional not only to the quality, but also to the quantity of the specimen (Daley *et al*, 1986; Lynch and Morris, 1990). Curling artefacts are common in samples that are too small, making the correct orientation difficult during the embedding procedure (Ficarra, McClintock and Hansen, 1987). Curling is sometimes less of a problem when thin lesions have relatively thick keratotic surfaces (Zegarelli, 1978). Small samples can reduce their size during processing and fixing (Daley *et al*, 1986; Moenning and Tomich, 1992). Tiny specimens are easily lost in handling and are always difficult to orient, especially after distortion and shrinkage during fixation and processing (Bernstein, 1978). This problem can be prevented if, after the biopsy, it is placed with the mucosal surface up on a piece of the sterile paper that held the suture material.

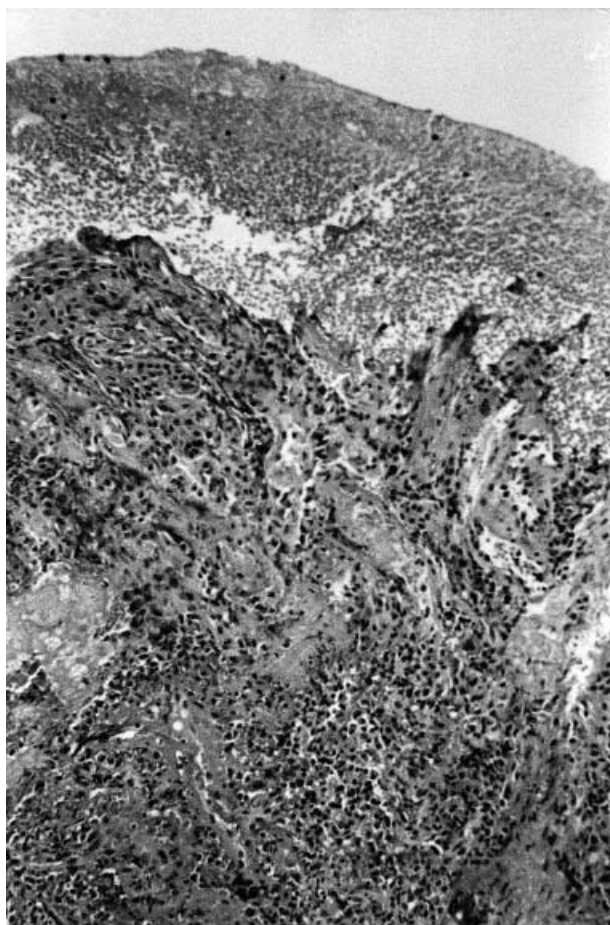
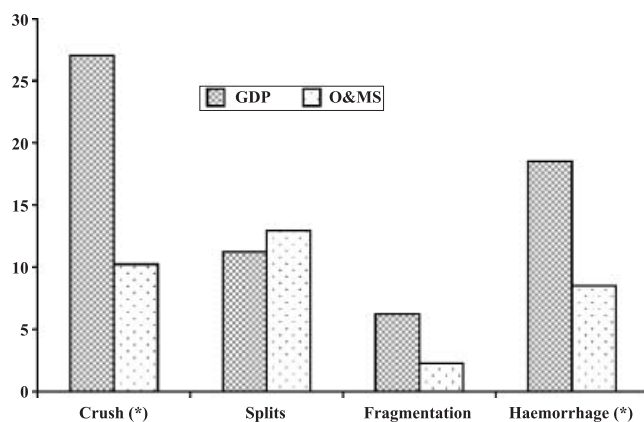


Figure 3 Oral mucosa without epithelium with haemorrhage and crush of the superficial areas (H&E; 400×)



(*) statistically significant

Figure 4 Artefacts found in specimens obtained by GDPs or O&MSs (% artefacts by each type)

The specimen is allowed to remain unfixed for a short time while the incision is being sutured (Zegarelli, 1978; Moenning and Tomich, 1992).

Previous reports suggest that GDPs should refer the patients needing biopsies of the lesions located on the

Table 3 Concordance between clinical and pathological diagnoses achieved by GDPs and O&MSs

Type of pathology	General dental practitioners		Oral and maxillofacial surgeons	
	n (%)	Kappa (95% CI)	n (%)	Kappa (95% CI)
Inflammatory	68 (38.4)	0.95 (0.80–1.00)	31 (17.5)	1.00 (0.85–1.00)
Benign tumour	36 (20.3)	0.98 (0.84–1.00)	48 (27.1)	0.99 (0.84–1.00)
Oral precancer	51 (28.8)	0.90 (0.75–1.00)	31 (17.5)	0.98 (0.83–1.00)
Oral cancer	22 (12.4)	0.78 (0.64–0.93)	67 (37.9)	1.00 (0.85–1.00)

floor of the mouth to a specialist (Kahn *et al*, 1998). However, our results indicate that the location of the lesion does not determine the number of artefacts observed in incisional oral biopsies.

Competent knowledge of the clinical aspects of oral cancer has been quite satisfactorily achieved among dentists in several European countries and the USA (Yellowitz *et al*, 1998). Our study seems to confirm this, as GDPs have obtained a high concordance between clinical and pathological diagnoses both in oral cancer and precancer. However, there is a discrepancy between knowledge and clinical behaviour. In this sense, most of the GDPs in Spain, considered biopsy to be a procedure that should be undertaken on a routine basis in dental surgeries, but only 24.6% had undertaken at least one biopsy per year to demonstrate or rule out oral cancer or precancer (Seoane *et al*, 1999).

The indication to undertake oral biopsies in general dental practice setting when cancer is suspected is controversial in scientific literature. Several authors consider the most useful investigations for suspected oral malignancy are representative biopsies, which may be taken from more than one area, guided by ancillary procedures like toluidine blue mouthrinse (Porter and Scully, 1998; Zakrzewska, 1999). However, other reports give clear directions to the GDP: do not panic, do not biopsy and refer immediately to multidisciplinary head and neck oncology clinics (McAndrew, 1998; Cox, Alcock and Corbridge, 1999).

Unresolved issues regarding clinical oral examination for early preneoplastic and neoplastic disease include criteria for a decision to perform a biopsy (Gould, 2002). The elicited clinical knowledge, the quality of the samples sent to the pathologists, together with legal reasons (involving litigation by plaintiffs suing dentists alleging that the dentist should, but did not, perform a biopsy; Lydiatt, 2002) seem to suggest the advisability for the GDP to perform diagnostic biopsies.

References

- Bermejo Fenoll A (1998). *Medicina bucal*. Síntesis: Madrid.
- Bernstein ML (1978). Biopsy technique: the pathological considerations. *J Am Dent Assoc* **96**: 438–443.
- Cowan J, Gregg TA, Kee F (1995). Prevention and detection of oral cancer: the views of primary care dentists in Northern Ireland. *Br Dent J* **179**: 338–342.
- Cox G, Alcock C, Corbridge R (1999). Treatment of oral cancer: biopsy under local anaesthetic is inadequate. *BMJ* **319**: 706.

- Daley TD, Lovas JL, Wysocki GP (1986). Oral biopsy technique. The pathologist's perspective. *J Can Dent Assoc* **52**: 591–595.
- Eversole LR (1997). Laser artefacts and diagnostic biopsy. *Oral Surg Oral Med Oral Pathol* **83**: 639–641.
- Ficarra G, McClintock B, Hansen LS (1987). Artefacts created during oral biopsy procedures. *J Craniomaxillofac Surg* **15**: 34–37.
- Fleiss JL (1986). *The Design and Analysis of Clinical Experiments*. John Wiley & Sons: New York.
- Gould AR (2002). Early detection of oral premalignant disease and oral cancer: refining the process. *Oral Surg Oral Med Oral Pathol* **94**: 397–398.
- Jaber MA, Diz-Dios P, Vazquez-García E et al (1997). Spanish dental students knowledge of oral malignancy and premalignancy. *Eur J Dent Educ* **1**: 167–171.
- Kahn MA, Lynch DP, Turner JE et al (1998). The dos and don'ts of an oral mucosal biopsy performed by the general dentist. *J Tenn Dent Assoc* **78**: 28–31.
- Lydiatt DD (2002). Cancer of the oral cavity and medical malpractice. *Laryngoscope* **112**: 816–919.
- Lynch DP, Morris LF (1990). The oral mucosal punch biopsy: indications and technique. *J Am Dent Assoc* **121**: 145–149.
- Margarone JE, Natiella JR, Natiella RR (1984). Primates as a teaching model for biopsy. *J Dent Educ* **48**: 568–570.
- Margarone JE, Natiella JR, Vaughan CD (1985). Artefacts in oral biopsy specimens. *J Oral Maxillofac Surg* **43**: 163–172.
- McAndrew PG (1998). Oral cancer biopsy in general practice. *Br Dent J* **185**: 428.
- Moenning JE, Tomich CE (1992). A technique for fixation of oral mucosal lesions. *J Oral Maxillofac Surg* **50**: 1345.
- Moule I, Parsons PA, Irvine GH (1995). Avoiding artefacts in oral biopsies: the punch biopsy versus the incisional biopsy. *Br J Maxillofac Surg* **33**: 244–247.
- Porter SR, Scully C (1998). Early detection of oral cancer in the practice. *Br Dent J* **185**: 72–73.
- Seoane J, Varela-Centelles P, Diz Dios P (1999). Experience and knowledge of oral cancer and precancer among dentists in northwestern Spain. *J Cancer Educ* **14**: 175–176.
- Seoane J, Varela-Centelles P, Ramirez JR et al (2002). Artefacts produced by suture traction during incisional biopsy of oral lesions. *Clin Otolaryngol* **27**: 549–553.
- Warnakulasuriya KAAS, Johnson NW (1999). Dentists and oral cancer prevention in the UK: opinions, attitudes and practices to screening for mucosal lesions and to counselling patients on tobacco and alcohol use: baseline data from 1991. *Oral Dis* **5**, 10–14.
- Yellowitz J, Horowitz AM, Goodman HS et al (1998). Knowledge, opinions and practices of general dentists regarding oral cancer: a pilot survey. *J Am Dent Assoc* **129**, 579–583.
- Zakrzewska JM (1999). Oral cancer. *BMJ* **318**: 1051–1054.
- Zegarelli DJ (1978). Common problems in biopsy procedure. *J Oral Surg* **36**: 644–647.

Copyright of Oral Diseases is the property of Blackwell Publishing Limited and its content may not be copied or emailed to multiple sites or posted to a listserv without the copyright holder's express written permission. However, users may print, download, or email articles for individual use.